

Soft Tissue Profile Changes After Bilateral Sagittal Split Osteotomy for Mandibular Advancement: A Systematic Review

*Christof Urs Joss, DMD, MSc,**

Isabella Maria Joss-Vassalli, DMD,†

Stavros Kiliaridis, Dr Odont, PhD,‡ and

Anne Marie Kuijpers-Jagtman, DDS, PhD, FDSRCS(Eng)§

Purpose: The purpose of the present systematic review was to evaluate the soft tissue/hard tissue ratio in bilateral sagittal split advancement osteotomy (BSSO) with rigid internal fixation (RIF) or wire fixation (WF).

Materials and Methods: The databases PubMed, Medline, CINAHL, Web of Science, Cochrane Library, and Google Scholar Beta were searched. From the original 711 articles identified, 12 were finally included. Only 3 studies were prospective and 9 were retrospective. The postoperative follow-up ranged from 3 months to 12.7 years for RIF and 6 months to 5 years for WF.

Results: The short- and long-term ratios for the lower lip to lower incisor for BSSO with RIF or WF were 50%. No difference between the short- and long-term ratios for the mentolabial-fold to point B and soft tissue pogonion to pogonion could be observed. It was a 1:1 ratio. One exception was seen for the long-term results of the soft tissue pogonion to pogonion in BSSO with RIF; they tended to be greater than a 1:1 ratio. The upper lip mainly showed retrusion but with high variability.

Conclusions: Despite a large number of studies on the short- and long-term effects of mandibular advancement by BSSO, the results of the present systematic review have shown that evidence-based conclusions on soft tissue changes are still unknown. This is mostly because of the inherent problems of retrospective studies, inferior study designs, and the lack of standardized outcome measures. Well-designed prospective studies with sufficient sample sizes that have excluded patients undergoing additional surgery (ie, genioplasty or maxillary surgery) are needed.

© 2010 American Association of Oral and Maxillofacial Surgeons
J Oral Maxillofac Surg 68:1260-1269, 2010

The major indication for bilateral sagittal split advancement osteotomy (BSSO) is the advancement and setback of the mandible to correct skeletal Class II and III defects.^{1,2} Moderate to severe mandibular retrognathism and prognathism often require a combined orthodontic and surgical approach for optimal function and best esthetic results. Generally, when an orthognathic surgery case is planned, the skeletal tissues are used to determine the amount of change

necessary to provide the appropriate soft tissue profile change.

Orthognathic surgery has the potential to change facial esthetics. Surgical procedures to correct skeletal deformities result in changes in the shape and position of the overlying soft tissues. The patient seeking combined surgical-orthodontic therapy needs precise information about the facial changes that will appear after treatment to decide whether to undergo

*PhD Student, Department of Orthodontics and Oral Biology, Radboud University Nijmegen Medical Center, Nijmegen, The Netherlands; and Department of Orthodontics, University of Geneva, Geneva, Switzerland.

†Member of Senior Staff, Department of Orthodontics and Dento-facial Orthopedics, University of Bern, Bern, Switzerland.

‡Head of Department, Department of Orthodontics, University of Geneva, Geneva, Switzerland.

§Head of Department, Department of Orthodontics and Oral

Biology, Radboud University Nijmegen Medical Center, Nijmegen, The Netherlands.

Address correspondence and reprint requests to Dr Joss: Faculté de Médecine, Section de Médecine Dentaire, rue Barthélémy-Menn 19, Geneva CH-1205 Switzerland; e-mail: christofjoss@hotmail.com

© 2010 American Association of Oral and Maxillofacial Surgeons

0278-2391/6806-0008\$36.00/0

doi:10.1016/j.joms.2010.01.005

the treatment. Therefore, accurate prediction of the postoperative facial profile has become an essential part of the diagnostic and treatment planning procedure of combined surgical-orthodontic therapy.

Currently, different computer imaging algorithms and programs allow one to provide the patient and clinician with some idea of the expected treatment result. The relationship and behavior of the soft tissues in relationship to the underlying skeletal movements shown in different studies should be the database for these programs and techniques. Nevertheless, the accuracy of the prediction is highly dependent on the clinician's knowledge of the soft tissue response to skeletal repositioning. Recently, a trend has been seen for quantifying the soft tissue profile changes using a 3-dimensional evaluation (ie, optical laser surface scanners,³ stereophotogrammetry with 2 cameras,⁴ or computed tomography-assisted imaging⁵).

Although the skeletal stability in BSSO advancements⁶ has been systematically reviewed, the soft tissue profile after mandibular advancement surgery has not yet been systematically reviewed.

The aim of the present study was to systematically review the published data on the soft tissue profile after BSSO to advance the mandible using different types of rigid internal fixation (RIF) and wire fixation (WF).

The specific research questions were to determine 1) the relationship between the soft tissue and skeletal movements in BSSO advancement surgery with RIF and WF; 2) whether a difference exists between the short- and long-term results; 3) the influence of genioplasty; and 4) whether any difference in the outcomes results from using RIF versus WF.

Materials and Methods

LITERATURE SEARCH

A literature search was performed using the following databases: PubMed (from 1966 to the third week of March 2009), Medline (from 1966 to the third week of March 2009), Google Scholar Beta (to the third week of March 2009), EMBASE Excerpta Medica (from 1980 to the third week of March 2009), CINAHL (from 1982 to the third week of March 2009), Web of Science (from 1945 to the third week of March 2009), and CENTRAL of the Cochrane Library (to the third week of March 2009), to identify articles reporting BSSO advancement surgical-orthodontic treatment with RIF or WF and soft/hard tissue ratios. Free text words and MeSH terms were used. The heading sequence ("BSSO" OR "bilateral sagittal split osteotomy" OR "sagittal split osteotomy" OR "mandibular osteotomy" OR "orthognathic surgery") AND ("soft tissue" OR "soft tissue profile" OR "soft tissue relapse" OR "relapse" OR "stability") AND "cephalometry" [MeSH] NOT "distraction") was

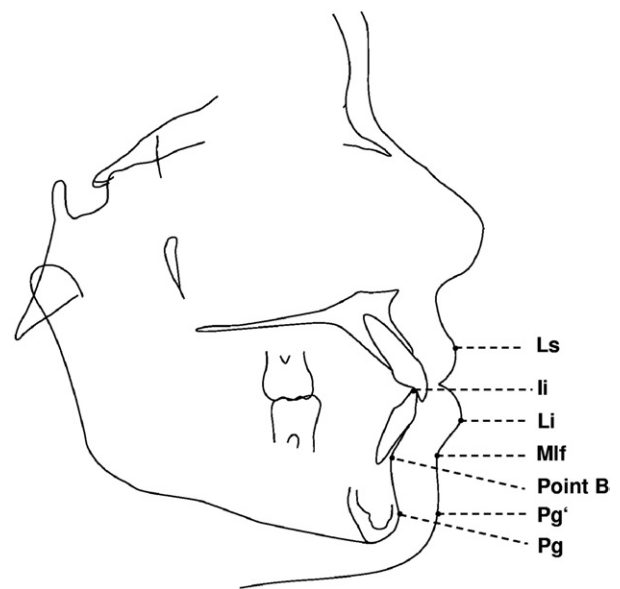


FIGURE 1. Reference points used for soft to hard tissue ratios after BSSO for mandibular advancement.

Joss et al. Soft Tissue Profile Changes After BSSO. J Oral Maxillofac Surg 2010.

selected. No exclusion of articles because of the language used was performed. To complete the search, the references of each selected publication on the soft tissue profile after BSSO advancement surgical-orthodontic treatment were searched by hand.

SELECTION CRITERIA

The following inclusion criteria were chosen initially to select potential articles from the published abstract results: 1) human clinical trials; 2) no syndromic or medically compromised patients, and no diseases; 3) no case reports, case series of fewer than 10 patients, descriptive studies, review articles, or opinion articles; 4) no surgical intervention other than BSSO for mandibular advancement (ie, Le Fort I, other types of mandibular surgery) with RIF or WF; and 5) lateral cephalograms used for horizontal soft tissue stability, which was measured at the pogonion (Pg) and/or point B and/or lower incisor to their corresponding soft tissue points (Fig 1). Genioplasty was accepted. In the case of duplicate publications in more than one language, it was decided to use the publication in English.

The articles that met the inclusion criteria were divided into 2 groups according to the method of fixation (RIF or WF). Furthermore, we distinguished between those with short- and long-term results, for which a cutoff value of 2 years was chosen to separate the short- and long-term studies.^{6,7} In cases of more than one publication of the same patient group for the same postoperative follow-up period, the most informative and relevant article was included.

Table 1. SEARCH RESULTS FROM DATABASES

Database	Abstract Series Found	Abstract Series Selected	Abstracts Not in PubMed
PubMed	260	79	1
Medline	243	68	1
Google Scholar Beta	104	28	0
EMBASE Excerpta Medica	62	17	0
CINAHL	32	8	0
Web of Science	10	3	0
Cochrane	0	0	0
Total	711	203	2

Joss et al. *Soft Tissue Profile Changes After BSSO. J Oral Maxillofac Surg* 2010.

DATA EXTRACTION

The data were extracted and methodologically assessed for quality independently by 2 observers (C.J. and I.J.-V.). The data were recorded on specially designed data extraction forms. First, the abstracts were reviewed without considering the number of patients reported. Articles that apparently fulfilled the inclusion criteria and the articles for which the title or abstract did not present enough relevant information were obtained in full text. Second, the following data were extracted from the full-text articles: year of publication; study design; follow-up; number and mean age of patients; ethnic background of patients; number of surgeons operating; type of RIF or WF; combined surgical-orthodontic patients with BSSO and RIF or WF for mandibular advancement; presence of orthodontic treatment; maxillomandibular fixation; genioplasty; intraoperative splint and presence in postoperative radiographs; mean skeletal advancement; mean ratio between the lower incisor, point B, pogonion, and their corresponding soft tissue points (labrale inferior, mentolabial fold, and soft tissue pogonion [Pg']); ratios for labrale superior to lower incisor, points B or Pg when present; correlations between the soft tissue points and different variables such as age, gender, relapse, and so forth. Missing ratios between the soft and hard tissue points were calculated from the published data.

To assess the methodologic soundness of each article, a quality evaluation modified from the methods described by Jadad et al⁸ and Petren et al⁹ was performed using the following characteristics: study design; sample size and previous estimate of sample size; selection descriptions; withdrawals (dropouts); valid methods; confounding factors (eg, genioplasty, presence of a splint in the immediate postoperative radiographs, and brackets bonded on teeth in follow-up photographs); method error analysis; blinding in measurements; and adequate statistical analysis.

The quality was categorized as low, medium, or high. In the event of a discrepancy regarding the inclusion criteria, quality evaluation, or extracted data between the observers, a consensus decision was made.

Results

SEARCH RESULTS

The search strategy resulted in 711 articles, and the number of abstracts selected was 203 (Table 1). The titles of the eliminated 508 articles were not topic related. The Quorum-flow diagram gives an overview of the selection process (Fig 2). A manual search of the references revealed 64 studies, and 57 were selected and studied with the 85 articles derived from the electronic search. Potentially, 18 articles were appropriate to include. However, 6 articles were finally rejected because the patients had undergone other types of surgery or the exact surgical procedure was not described (2 studies^{10,11}), advancement and setback surgery were mixed (1 study¹²), only white females had been included (2 studies^{13,14}), or insufficient patient and/or surgical data (3 studies^{12,13,15}). Finally, 12 suitable studies¹⁶⁻²⁷ (9 articles from the electronic database search and 3 articles from the manual search) were included (Table 2).

QUALITY ANALYSIS

Only 3 studies had a prospective study design,^{17,18,22} and only 1 study was a multicenter randomized, clinical

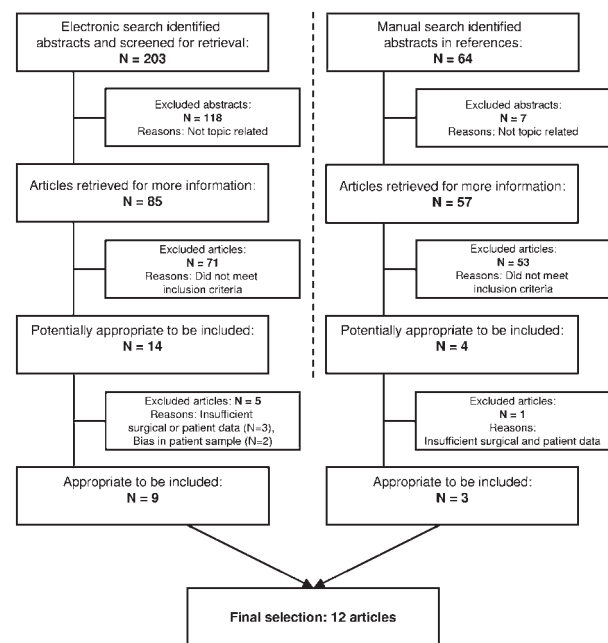


FIGURE 2. QUORUM-flow diagram.

Joss et al. *Soft Tissue Profile Changes After BSSO. J Oral Maxillofac Surg* 2010.

Table 2. ARTICLES (N = 12) INCLUDED IN REVIEW

Investigators	Year	Country	Study Design	Judged Quality Standard
Alves et al ¹⁶	2008	Brazil	CT, R	Low
Joss and Thüer ¹⁷	2008	Switzerland	CT, P	Medium
Dolce et al ¹⁸	2003	US	MCT, RCT	High
Hamada et al ¹⁹	2001	Japan	CT, R	Low
Mobarak et al ²⁰	2001	Norway	CT, R	Low
Pangrazio-Kulbersh et al ²¹	2001	US	CT, R	Low
Thüer et al ²²	1994	Switzerland	CT, P	Medium
Ewing and Ross ²³	1992	Canada	CT, R	Low
Athanasios et al ²⁴	1990	Denmark	CT, R	Low
Dermaut and De Smit ²⁵	1989	Belgium	CT, R	Low
Hernandez-Orsini et al ²⁶	1989	US	CT, R	Low
Mommaerts and Marxer ²⁷	1987	Switzerland	CT, R	Low

Abbreviations: CT, clinical trial; R, retrospective study; P, prospective study; MCT, multicenter clinical trial; RCT, randomized clinical trial.

Joss et al. Soft Tissue Profile Changes After BSSO. J Oral Maxillofac Surg 2010.

trial.¹⁸ The ethnic background of the patients in all reviewed studies was mainly white, except for the study by Hamada et al¹⁹ on Asian subjects.

Table 2 lists the research quality or methodologic soundness of the 12 studies. It was low in 9 studies, medium in 2 studies, and high in 1 study. The most obvious findings were small sample sizes, implying low power, a lack of error analysis, no blinding of measurements, and deficient or a lack of statistics. Furthermore, no study declared any power analysis. Seven studies^{16,18,20,22,25-27} were judged to have an adequate sample size, ranging from 30 to more than 90.

In all studies, the methods used to detect and analyze the postoperative ratios between the soft and hard tissue were valid and well known. However, 3 studies did not include a method error analysis,^{18,23,26} and none of the studies used blinding in the measurements. Correlation statistics for other variables such as gender, age, and so forth were used in 6 studies.^{17-20,22,27}

Considering the confounding variable, genioplasty, 1 study declared that additional genioplasty was performed in only 2 patients; however, point Pg, Pg', menton (Me), and soft tissue menton (Me') were excluded for data analysis.²² Also, in 1 study,¹⁹ it was not clear whether some patients with genioplasty had been included. In another study,¹⁸ patients with additional genioplasty were grouped together. None of the studies analyzed the presence of bonded brackets and its influence in the follow-up cephalograms.

Another confounding variable was the presence of a splint in the immediate postoperative radiographs. This did not play an important role because this systematic review did not consider the immediate postoperative ratios. Nevertheless, the extracted data concerning the postoperative splint has been discussed for accuracy.

Surgical splints were not used in some studies,^{16,17,22} and in the study by Mobarak et al,²⁰ only in some patients were splints present in the postoperative radiographs. The immediate postoperative data from these patients were excluded.²⁰ In 1 study,¹⁸ the lateral cephalogram was taken with the splints in place 1 week after surgery. No other studies commented on the presence of a splint in the immediate postoperative radiographs nor did they compensate for its presence. Hence, the autorotation of the mandible caused by removal of the splint, depending on its thickness, would result in a relative anterior displacement of the mandible, and this must be considered when assessing relapse.^{28,29} Surgical splints could have an effect on the soft tissue profile of the lips and mentolabial fold, depending on the thickness and design, and cause an increase in the anterior facial height. The removal of the splint often results in autorotation and advancement of point B and Pg, as described in studies on the skeletal stability after BSSO for mandibular advancement.^{30,31}

FOLLOW-UP PERIOD

The range of follow-up was 3 months¹⁹ to 12.7 years¹⁷ for RIF (Table 3) and 6 months¹⁸ to 5 years¹⁸ for WF (Table 4). For RIF, only 2 studies reported the long-term results,^{17,20} and 1 study reported the short- and long-term results.¹⁸ For WF, only 1 study had long-term results.¹⁸

SHORT-TERM SOFT TISSUE RATIOS

The short-term ratios for RIF without genioplasty (Table 3) were -2%²⁶ to 29%¹⁶ for the upper lip to incision inferior, 35%¹⁸ to 108%¹⁶ for the lower lip to the incision inferior, 88%²² to 111%¹⁸ for the mentolabial fold to point B, 90%¹⁹ to 124%¹⁶ for Pg' to Pg.

Table 3. SUMMARIZED DATA OF 8 STUDIES WITH BSSO ADVANCEMENT SURGERY WITH RIF

Study	Surgery	Surgeons (n)	Patients (n)	Mean Age (Range) (yr)	Follow-Up	Ls	Li/Ii	Mlf/B	Pg'/Pg
Alves et al, ¹⁶ 2008	2 titanium bicortical screws, no GP, no splints	1	36	23	13.2 mo	29% (Ls/Ii) 23% (Ls/Pg)	108%	NR	124%
Joss and Thüer, ¹⁷ 2008	3 titanium lag bicortical screws (Ø 3.5 mm), no GP, MMF for 4-6 days, no splints	4	16	21.4 (17.0-31.1)	12.7 yr	-67% (Ls/Ii) -67% (Ls/B) -76% (Ls/Pg)	55%	94%	119%
Dolce et al, ¹⁸ 2003	BSSO, groups for RIF with or without GP, 3 bicortical screws (Ø 2 mm), MMF 5-7 days	NR	29 (RIF, GP) 28 (RIF, no GP)	33.1 ± 11.3 28.2 ± 8.8	5 yr	NR	57% 46%	112% 111%	86% 127%
		NR	34 (RIF, GP)	NR	2 yr	NR	36%	114%	81%
		NR	39 (RIF, no GP)	NR	1 yr	NR	31%	102%	106%
		NR	31 (RIF, GP)	NR	1 yr	NR	54%	119%	84%
		NR	40 (RIF, no GP)	NR	6 mo	NR	35%	108%	106%
Hamada et al, ¹⁹ 2001	BSSO with RIF (screws), 1 patient with WF, GP?	NR	34 (RIF, GP) 41 (RIF, no GP)	NR	3 mo	NR	62% 59%	120% 111%	85% 102%
		NR	14	23 yr, 11 mo	3 mo	NR	48%	89%	90%
Mobarak et al, ²⁰ 2001	3 Salzburg titanium bicortical lag screws (Ø 2.0 mm) and washers, no GP, with or without splints, no MMF	7	61	28.2 ± 9.3 (16.2-50.9)	3 yr				
						High -17% (Ls/Ii) -14% (Ls/B) -13% (Ls/Pg)	60% (high)	86% (high)	102% (high)
						Med -10% (Ls/Ii) -11% (Ls/B) -11% (Ls/Pg)	60% (med)	93% (med)	111% (med)
						Low -18% (Ls/Ii) -20% (Ls/B) -26% (Ls/Pg)	60% (low)	95% (low)	111% (low)
Pangrazio-Kulbersh et al, ²¹ 2001	Bicortical screws, no GP, splint	1	20	24.4 (16.7-39.4)	1 yr	NR	61%	93%	100%
Thüer et al, ²² 1994	3 titanium lag screws (Ø 3.5 mm), MMF for 4-6 days, 2 with GP (but excluded for evaluation of Pg, Pg'), no splints intra- or postoperatively	4	30	20 yr, 5 mo (17-32.5)	13 mo	NR	66%	88%	100%
Hernandez-Orsini et al, ²⁶ 1989	BSSO with RIF (type missing), no GP	NR	31	28.3 (14-48)	8 mo	-2% (Ls/Ii) -2% (Ls/B) -2% (Ls/Pg)	43%	93%	94%

Abbreviations: Ls, labrale superior; Li, labrale inferior; Ii, incision inferior; Mlf, mentolabial fold; B, point B; Pg', soft tissue pogonion; Pg, pogonion; GP, genioplasty; WF, wire fixation; NR, not reported; Ø, diameter; MMF, maxillomandibular fixation; BSSO, bilateral sagittal split advancement osteotomy; RIF, rigid internal fixation; Low, low-angle cases; High, high-angle cases; Med, medium-angle cases.

Negative values imply posterior movement; positive values, anterior movement.

Joss et al. *Soft Tissue Profile Changes After BSSO*. *J Oral Maxillofac Surg* 2010.

Table 4. SUMMARIZED DATA OF 5 STUDIES WITH BSSO ADVANCEMENT SURGERY WITH WF

Study	Surgery	Surgeons (n)	Patients (n)	Mean Age (Range) (yr)	Follow-Up	Ls	Li/Li	Mi/B	Pg'/Pg
Dolce et al. ¹⁸ 2003	BSSO, groups with/without GP, WF with 6 wk MMF	NR	18 (WF, GP)	29.3 ± 10.5	5 yr	NR	13%	101%	71%
			15 (WF, no GP)	28.0 ± 10.2			80%	96%	107%
			23 (WF, GP)	NR	2 yr	NR	26%	93%	76%
			25 (WF, no GP)	NR	1 yr	NR	38%	82%	84%
			23 (WF, GP)	NR	1 yr	NR	36%	104%	71%
Ewing and Ross, ²³ 1992	BSSO with WF, MMF, no GP	1	25 (WF, no GP)	NR	6 m	NR	58%	87%	82%
			24 (WF, GP)	NR	1 yr	NR	56%	119%	81%
Athanasίου et al. ²⁴ 1990	BSSO with WF, MMF for 6 wk, no GP	1	14	19.5 (11.2-35.5) for whole group (n = 31) (16-41)	1 yr	NR	63%	93%	77%
			14		1 yr	NR	97%	104%	
Dermaut and De Smit, ²⁵ 1989	BSSO with WF, MMF for 6 wk, no GP	NR	31	Females, 17 yr, 6 mo (14-25) Males, 17 yr, 9 mo (15-26)	1 yr	-28% (Ls/I) -44% (Ls/B) -60% (Ls/Pg)	26%	119%	110%
			35		1 yr	NR	56%	106%	103%
Mommaerts and Marxer, ²⁷ 1987	BSSO with WF, no GP, no splint	NR		21.5 ± 8.5	1 yr	NR	56%	106%	103%

Abbreviations as in Table 3.

Negative values indicate posterior movement; positive values, anterior movement.

Joss et al. *Soft Tissue Profile Changes After BSSO*. *J Oral Maxillofac Surg* 2010.

The short-term ratios for WF without genioplasty (Table 4) were -28%²⁵ for the upper lip to the incision inferior, 26%²⁵ to 63%¹⁸ for the lower lip to incision inferior, 87%¹⁸ to 119%²⁵ for the mentolabial fold to point B, and 77%¹⁸ to 110%²⁵ for Pg' to Pg.

The results from the study groups that included only patients with genioplasty were not considered for these listings of RIF and WF.¹⁸

LONG-TERM SOFT TISSUE RATIOS

The long-term ratios for RIF without genioplasty (Table 3) were -10%²⁰ to -67%¹⁷ for the upper lip to incision inferior, 31%¹⁸ to 60%²⁰ for the lower lip to the incision inferior, 86%²⁰ to 111%¹⁸ for the mentolabial fold to point B, and 102%²⁰ to 127%¹⁸ for Pg' to Pg.

The long-term ratios for WF without genioplasty (Table 4) were 38% to 80%¹⁸ for the lower lip to the incision inferior, 82% to 96%¹⁸ for the mentolabial fold to point B, and 84% to 107%¹⁸ for Pg' to Pg. No studies were found with the long-term ratios for WF of the upper lip.

CORRELATIONS

Correlation statistics were used in 6 studies.^{17-20,22,27} However, most studies used correlation statistics only to assess the relationship between the change in the hard and soft tissue structures.^{18-22,24,27} Interesting research questions such as the associations between the soft tissue changes and gender, preoperative age, low- and high-angle patients, and the amount of advancement were not addressed. In their long-term study, Joss and Thüer¹⁷ did not find any correlations between the soft tissue changes and preoperative age, gender, and the amount of advancement.

Discussion

Optimal treatment planning for maxillofacial surgery requires an understanding of the stability of the postoperative skeletal position and the soft tissue response to skeletal movement. The postoperative skeletal stability after BSSO for mandibular advancement was addressed earlier in a systematic review.⁶ It is difficult to exactly determine the changes in the soft tissue profile that are specific to BSSO for mandibular advancement when other, simultaneous, orthognathic surgical procedures, such as genioplasty or Le Fort I osteotomy, have been included. The inclusion in the present study of patients treated with either RIF or WF was thought to promote the possibility for their separate analysis and direct comparison in the short and long term. Clinical trends for fixating the proximal to the distal segment intraoperatively have shown an increased use of RIF instead of WF. The same trend was seen when reviewing the stud-

ies of soft tissue stability (ie, no recent studies of WF were found, with the exception of the randomized clinical trial by Dolce et al).¹⁸

The Quality of Reporting of Meta-analyses statement³² was used as the basis to report the present systematic review. Of the 12 included studies, only 1 randomized, clinical trial and 2 prospective studies were found. Therefore, at present, a meta-analysis of the data was impossible. To increase the power of our systematic review, it would have been necessary to include only randomized, clinical trials; prospective multicenter articles; or prospective clinical trials.

We tried to provide a summarized database for commercially available surgical prediction software packages for the mean ratios of soft tissue to hard tissue movements in BSSO for mandibular advancement, even though evidence to date is lacking. Thus, the present computer programs that attempt to predict the soft tissue profile have been based on weak evidence and 2-dimensional records of 3-dimensional phenomena. It might be possible that 3-dimensional imaging techniques will provide better insight in the near future. Furthermore, it would be necessary to standardize the outcome variables between centers, exclude or separate patients with genioplasty, evaluate the error of the method, standardize the superimposing of the lateral cephalograms (ie, the sella-nasion line minus 7°), and list all essential patient data and correlation statistics, as was partly noted in our earlier reviews.^{6,7}

In all the reviewed studies, the soft tissue prediction was, or could be, calculated as the ratio between the amount of change in the hard and soft tissue during the same interval. The relationship between the hard and soft tissue changes could be very complex because of differing soft tissue morphology, thickness combined with weight changes, posture, elasticity, and/or tonicity, which can vary from person to person.³³ Mobarak et al²⁰ showed that individual variability was greatest in small skeletal advancements or large skeletal relapses. However, problems that could evolve when using prediction software based on mean data from the studies included in the present systematic review could be the large individual variability in the soft tissue response.

Another problem is the question of whether we should use linear or nonlinear soft/hard tissue ratios in predictions as has been proposed and adopted by some software programs.³⁴ The idea behind the use of nonlinear ratios is that the soft tissue becomes more resistant to movements the more the mandible is advanced. For the chin, we could argue that the initial ratio would be rather high compared with the last ratio. However, contact of the lower lip to the upper lip and upper incisors is often present before surgery. The initial labrale inferior/incision inferior

ratios could be rather small, and the more the lower incisors are advanced, the greater the ratio. At present, the available data are not sufficient to support any of these hypotheses.

INFLUENCE OF GENIOPLASTY

Genioplasty can be a powerful adjunctive procedure to improve the facial profile. The question that arises is whether a difference occurs in soft tissue stability when BSSO for mandibular advancement is combined with genioplasty.

Genioplasty alone mainly has an effect on the Pg', and the mentolabial fold depth increases because of the treatment. The effects on the lips have been small, and no change in lip thickness was noted.³⁵ Depending on the type of genioplasty, it is possible to move Pg and point B anteriorly with its surrounding soft tissue. The anterior movement of point B could also influence the lower lip profile. Furthermore, the chin undergoes remodeling patterns in the area of the osteotomy depending on the type of genioplasty, which will result in more variability of the soft tissue profile.³⁶

Several studies^{18,23,37} have shown that adding another surgical procedure (ie, genioplasty) to BSSO would influence the results. Soft tissue scarring in the anterior chin region can be present in patients treated with genioplasty. It has been claimed that the scar contracture during the postoperative healing period might cause decreased soft tissue thickness compared with the preoperative measurements.³⁸ RIF in the form of miniplates adds more volume on the anterior surface of the chin bone and has an effect on the soft tissue profile and limits the exact location of the cephalometric landmarks. Therefore, the evaluation of patients undergoing BSSO with and without genioplasty as a single group is questionable.

Ewing and Ross²³ found, in their group of BSSO and genioplasty, that the results were much less consistent compared with the results from patients without genioplasty. They attributed these differences to the fact that the patients requiring genioplasty often had more severe cases, and the soft tissue drape in severe retrognathia is usually abnormal.²³ Greater edema from additional surgical manipulation such as genioplasty has been shown to have an effect on increased soft tissue advancement.^{18,33} Dolce et al¹⁸ compared 4 groups of patients with RIF with or without genioplasty and WF with or without genioplasty. They concluded that the soft tissue profiles of these 4 groups were not significantly different, even though 2 of these 4 groups had a considerable incidence of skeletal relapse.

SHORT-TERM VERSUS LONG-TERM RATIOS

When analyzing the long-term effects, the effect of aging and changes in soft tissue elasticity must be considered. Studies that have evaluated the soft tissue profile over time in nontreated patients found that the distance between the sella and the labrale superior increased in adulthood, that a loss of soft tissue tension occurred, and that the labrale superior moved downward.^{39,40} Also, a forward and downward movement of Pg' and Me' was found for both genders in adulthood. Males achieved a more prominent Pg' , a less accentuated mentolabial fold, a longer and more prominent lower lip, and a larger and more angular nose compared with females. Forsberg⁴¹ performed a longitudinal study of facial growth in those 24 to 34 years of age. During that period, the nose moved forward, with a retrusion of the lips and a posterior movement of Pg' . He reported that a close relationship between the changes in the soft tissue and underlying hard tissue could not be expected, because the soft tissues are also subject to the tension from the oral musculature and the amount of subcutaneous fat present at different ages.

The present systematic review has shown that the differences between the short- and long-term lower lip/lower incisors ratios for BSSO with RIF or WF were quite small (Fig 3). The ratios were all about 50%. No distinction was found between the short- and long-term ratios for the mentolabial fold or Pg' . Patients treated with WF and RIF had similar outcomes. It could be described as a 1:1 ratio for the mentolabial fold to point B and for Pg' to Pg. One exception was

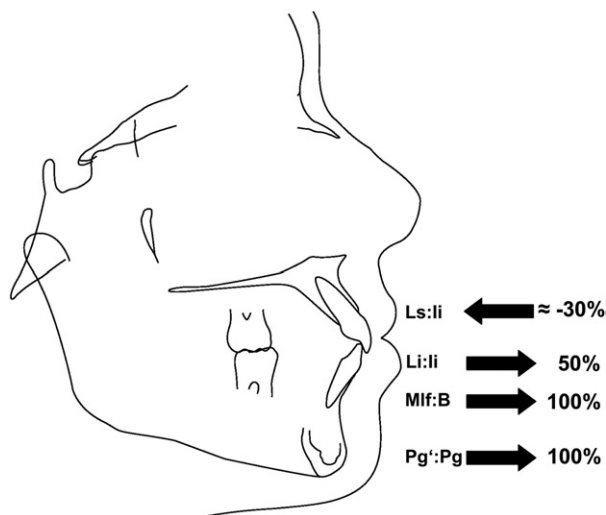


FIGURE 3. Soft to hard tissue ratios after BSSO for mandibular advancement with RIF or WF in the short- and long-term. Long-term ratios for $Pg':Pg$ tend to be higher than 100%. High variability is seen for the ratio of Ls compared to li, point B, or Pg.

Joss et al. Soft Tissue Profile Changes After BSSO. *J Oral Maxillofac Surg* 2010.

seen for the long-term results of Pg' in BSSO with RIF: the Pg'/Pg ratio tended to be greater than 100%. However, high variability was seen for the upper lip measured as a ratio to incision inferior, point B, or Pg.

In addition to the new mandibular soft tissue position, another important effect of BSSO is the postoperative swelling caused by the surgery. Thus, the immediate short-term soft tissue profile changes measured on the lateral cephalogram are always a combined effect of surgery, swelling, and the thickness of the orthodontic brackets. A more anterior soft tissue location would result in greater ratios for the soft tissue points immediately after surgery. Thus, it is advisable to consider an adequate healing period of several months for follow-up measurements. Dolce et al¹⁸ showed that the swelling caused by the surgery had begun to resolve by 8 weeks and had fully resolved by 6 months. The data in their 5-year, long-term study showed that the soft/hard tissue ratios vary over time. The soft to hard tissue correlations were strongest immediately after surgery and weaker later.

The effects of BSSO for mandibular advancement surgery on the upper lip are generally believed to be small^{20,26,27} and clinically irrelevant.²⁶ Nevertheless, the effects on the upper lip especially for low-angle cases should be considered.^{16,20} The initial anterior movement of the upper lip was probably related to postoperative edema, which gradually faded,^{14,20,26} but a net posterior relocation of the labrale superior was evident in the long term.^{17,20} An important confounding variable in the short term might have been the possible presence of orthodontic brackets on the buccal surface of the incisors. In summary, there appear to be some long-term effects of mandibular advancement surgery, probably combined with aging, on the upper lip position. A continuous lowering of the labrale superior described in the reviewed long-term studies can be attributed to the lack of soft tissue strength with age.^{17,20}

The lower lip failed to follow the total amount of mandibular advancement measured at the incision inferior compared with the mentolabial fold and Pg' . One explanation for this difference could be that preoperatively the lower lip position is mostly supported by the maxillary incisors and already maintained in a more anterior position. Another effect on lower lip support is created by the orthodontic brackets. Bracket removal after surgery at the end of orthodontic treatment will let the lower lip move posteriorly again. However, soft tissue profile photographic analysis showed that the presence of bonded labial appliances had no effect on the lip posture.⁴² Furthermore, the weak reproducibility of a relaxed lip position could also affect the

findings for the labrale inferior and could be a source of error.²⁶

Mobarak et al²⁰ found that preoperative lower lip thickness correlated significantly with the net change in its thickness. Thus, patients with a thicker lower lip were likely to have comparatively less anterior repositioning of the lip as it became thinner. The relatively smaller amount of lower lip advancement compared with the mentolabial fold and chin was partly related to the decrease in lower lip thickness. The accompanying decrease in the mentolabial fold depth was more pronounced in the low-angle than in the high-angle group, probably owing to the increase in anterior facial height by the surgery.

Several reviewed studies reported a tendency of the lower lip length to increase after mandibular advancement surgery.^{11,20,25} This could have resulted from an increase of the lower anterior facial height when the mandible was rotated clockwise in low-angle patients.

The long-term effects of the labrale inferior and stomion inferior in the vertical plane surprisingly showed a small upward movement. In the horizontal plane, the labrale inferior, mentolabial fold, and Pg' had a larger posterior movement, probably owing to skeletal relapse.^{17,18,20} The mentolabial fold and Pg' showed little change in either vertical direction.²⁰ In contrast, others described a downward movement.¹⁷ However, these values were missing in the other long-term study reviewed.¹⁸

Despite a large number of studies of the short- and long-term effects of mandibular advancement by BSSO, the results of the present systematic review showed that evidence-based conclusions of soft tissue changes are still lacking. This is mostly because of the inherent problems of retrospective studies, inferior study designs, and a lack of standardized outcome measures. Well-designed prospective studies with sufficient sample sizes that have excluded additional surgery (ie, genioplasty or maxillary surgery) are needed.

References

1. Trauner R, Obwegeser H: Zur Operationstechnik bei der Progenie und anderen Unterkieferanomalien. *Dtsch Zahn Mund und Kieferheilk* 23:1, 1955
2. Obwegeser H: The surgical correction of mandibular prognathism and retrognathia with consideration of genioplasty. *J Oral Surg* 10:677, 1957
3. Nkenke E, Vairaktaris E, Kramer M, et al: Three-dimensional analysis of changes of the malar-midfacial region after Le Fort I osteotomy and maxillary advancement. *Oral Maxillofac Surg* 12:5, 2008
4. Hajeer MY, Ayoub AF, Millett DT: Three-dimensional assessment of facial soft-tissue asymmetry before and after orthognathic surgery. *Br J Oral Maxillofac Surg* 42:396, 2004
5. Terajima M, Yanagita N, Ozeki K, et al: Three-dimensional analysis system for orthognathic surgery patients with jaw deformities. *Am J Orthod Dentofac Orthop* 134:100, 2008
6. Joss CU, Vassalli IM: Stability after bilateral sagittal split osteotomy advancement surgery with rigid internal fixation: A systematic review. *J Oral Maxillofac Surg* 67:301, 2009
7. Joss CU, Vassalli IM: Stability after bilateral sagittal split osteotomy setback surgery with rigid internal fixation: A systematic review. *J Oral Maxillofac Surg* 66:1634, 2008
8. Jasad AR, Moore RA, Carroll D, et al: Assessing the quality of reports of randomized clinical trials: Is blinding necessary? *Control Clin Trials* 17:1, 1996
9. Petren S, Bondemark L, Soderfeldt B: A systematic review concerning early orthodontic treatment of unilateral posterior crossbite. *Angle Orthod* 73:588, 2003
10. Lines PA, Steinhäuser EW: Soft tissue changes in relationship to movement of hard structures in orthognathic surgery: A preliminary report. *J Oral Surg* 32:891, 1974
11. Quast DC, Biggerstaff RH, Haley JV: The short-term and long-term soft-tissue profile changes accompanying mandibular advancement surgery. *Am J Orthod Dentofac Orthop* 84:29, 1983
12. Clemente-Panichella D, Suzuki S, Cisneros GJ: Soft to hard tissue movement ratios: Orthognathic surgery in a Hispanic population. *Int J Adult Orthodon Orthognath Surg* 15:255, 2000
13. Bailey LTJ, Collie FM, White RP: Long-term soft tissue changes after orthognathic surgery. *Int J Adult Orthodon Orthognath Surg* 11:7, 1996
14. Keeling SD, LaBanc JP, Van Sickels JE, et al: Skeletal change at surgery as a predictor of long-term soft tissue profile change after mandibular advancement. *J Oral Maxillofac Surg* 54:134, 1996
15. Albrechtsen L, Larsen B: Changes in lower lip cross-sectional area subsequent to mandibular advancement surgery. *Int J Adult Orthodon Orthognath Surg* 12:287, 1997
16. Alves PV, Mazucheli J, Vogel CJ, et al: How the lower face soft tissue changes after mandibular advancement or setback. *J Craniofac Surg* 19:593, 2008
17. Joss CU, Thuer UW: Stability of the hard and soft tissue profile after mandibular advancement in sagittal split osteotomies: A longitudinal and long-term follow-up study. *Eur J Orthod* 30:16, 2008
18. Dolce C, Hatch JP, Van Sickels JE, et al: Five-year outcome and predictability of soft tissue profiles when wire or rigid fixation is used in mandibular advancement surgery. *Am J Orthod Dentofac Orthop* 124:249, 2003
19. Hamada T, Motohashi N, Kawamoto T, et al: Two-dimensional changes in soft tissue profile following surgical mandibular advancement in Japanese retrognathic adults. *Int J Adult Orthodon Orthognath Surg* 16:272, 2001
20. Mobarak KA, Espeland L, Krogstad O, et al: Soft tissue profile changes following mandibular advancement surgery: Predictability and long-term outcome. *Am J Orthod Dentofac Orthop* 119:353, 2001
21. Pangrazio-Kulbersh V, Berger JL, Kaczynski R, et al: Stability of skeletal Class II correction with 2 surgical techniques: The sagittal split ramus osteotomy and the total mandibular subapical alveolar osteotomy. *Am J Orthod Dentofac Orthop* 120:134, 2001
22. Thüer U, Ingervall B, Vuillemin T: Stability and effect on the soft tissue profile of mandibular advancement with sagittal split osteotomy and rigid internal fixation. *Int J Adult Orthodon Orthognath Surg* 9:175, 1994
23. Ewing M, Ross BR: Soft tissue response to mandibular advancement and genioplasty. *Am J Orthod Dentofac Orthop* 101:550, 1992
24. Athanasiou AE, Gjørup H, Toutountzakis N: [Soft tissue and dentoskeletal profile changes associated with mandibular advancement osteotomy]. *Hell Periodontol Stomat Gnathoprosopike Cheir* 5:157, 1990
25. Dermaut LR, De Smit AA: Effects of sagittal split advancement osteotomy on facial profiles. *Eur J Orthod* 11:366, 1989
26. Hernandez-Orsini R, Jacobson A, Sarver DM, et al: Short-term and long-term soft tissue profile changes after mandibular advancement using rigid fixation techniques. *Int J Adult Orthodon Orthognath Surg* 4:209, 1989
27. Mommaerts MY, Marxer H: A cephalometric analysis of the long-term, soft tissue profile changes which accompany the advancement of the mandible by sagittal split ramus osteotomies. *J Craniomaxillofac Surg* 15:127, 1987

28. Blomqvist JE, Isaksson S: Skeletal stability after mandibular advancement: A comparison of two rigid internal fixation techniques. *J Oral Maxillofac Surg* 52:1133, 1994
29. Kierl MJ, Nanda RS, Currier GF: A 3-year evaluation of skeletal stability of mandibular advancement with rigid fixation. *J Oral Maxillofac Surg* 48:587, 1990
30. Watzke IM, Turvey TA, Phillips C, et al: Stability of mandibular advancement after sagittal osteotomy with screw or wire fixation: A comparative study. *J Oral Maxillofac Surg* 48:108, 1990
31. Abeloos J, De Clercq C, Neyt L: Skeletal stability following miniplate fixation after bilateral sagittal split osteotomy for mandibular advancement. *J Oral Maxillofac Surg* 51:366, 1993
32. Moher D, Cook DJ, Eastwood S, et al: Improving the quality of reports of meta-analyses of randomised controlled trials: The QUOROM statement. Quality of Reporting of Meta-analyses. *Lancet* 354:1896, 1999
33. Dolce C, Johnson PD, Van Sickels JE, et al: Maintenance of soft tissue changes after rigid versus wire fixation for mandibular advancement, with and without genioplasty. *Oral Surg Oral Med Oral Pathol Oral Radiol Endod* 92:142, 2001
34. Smith JD, Thomas PM, Proffit WR: A comparison of current prediction imaging programs. *Am J Orthod Dentofac Orthop* 125:527, 2004
35. Shaughnessy S, Mobarak KA, Hogevoid HE, et al: Long-term skeletal and soft-tissue responses after advancement genioplasty. *Am J Orthod Dentofac Orthop* 130:8, 2006
36. Precious DS, Armstrong JE, Morais D: Anatomic placement of fixation devices in genioplasty. *Oral Surg Oral Med Oral Pathol* 73:2, 1992
37. Dolce C, Hatch JP, Van Sickels JE, et al: Rigid versus wire fixation for mandibular advancement: Skeletal and dental changes after 5 years. *Am J Orthod Dentofac Orthop* 121:610, 2002
38. Polido WD, de Clairefont Regis L, Bell WH: Bone resorption, stability, and soft-tissue changes following large chin advancements. *J Oral Maxillofac Surg* 49:251, 1991
39. Behrents RG: Growth in the aging craniofacial skeleton, *in* McNamara JA (ed): Monograph 17, Craniofacial Growth Series. Ann Arbor, MI, University of Michigan, 1985
40. Behrents RG: An atlas of growth in the aging craniofacial skeleton, *in* McNamara JA (ed): Monograph 18, Craniofacial Growth Series. Ann Arbor, MI, University of Michigan, 1985
41. Forsberg CM: Facial morphology and ageing: A longitudinal cephalometric investigation of young adults. *Eur J Orthod* 1:15, 1979
42. Abed Y, Har-Zion G, Redlich M: Lip posture following debonding of labial appliances based on conventional profile photographs. *Angle Orthod* 79:235, 2009